


Compiled by Geoffrey M Knight



Experimental use of zirconia as a reinforcing material for direct resin bridges

Nothing works 100 per cent of the time in all clinical situations and there are occlusions that prove too challenging for direct resin bridges. In such cases the options are to either consider an alternative treatment plan or fit the abutment tooth with a circumferential metal ring with an extension arm to attach the pontic too. In over 20 years of constructing these inserts, the first fracture of the metal reinforcing arms is still to occur.

While these bridges are predictable, the metal ring on the pontic is challenging to mask and usually creates a compromise in aesthetics of the finished bridge.

The availability of zirconia as a reinforcing frame for these bridges opens new challenges and furthers the potential of reinforced direct resin bridges.

Clinical case

This is a patient of long standing who for various and complex reasons has been unable to stabilize his oral environment. Embarking upon a complex restorative treatment plan would certainly not be in his best interests until his mouth had become stabilized. It was considered appropriate in this

situation to provide a relatively simple, inexpensive solution for a missing upper lateral incisor.

A series of fibre reinforced resin bridges that had been placed at this site had all succumbed to his nocturnal bruxing. Figure 1 shows the preparation of the canine and first premolar as abutments. The white gingiva is due to an application of Trichloroacetic acid to control gingival exudates during preparation of the abutments. Both teeth have been root filled and fibre posts have been inserted into the root canals to assist with retention of the resin modified glass ionomer cement cores.

Rubber base impressions were taken of the upper and lower arches and a wax registration bite was taken to assist the laboratory in the construction of the reinforcing arm.

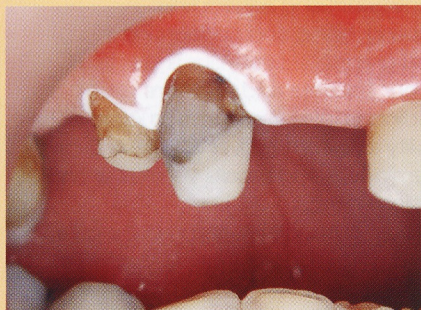

Fig 1. Tooth preparation of canine and bicuspid for direct zirconia reinforced resin bridge.



Fig 2. Zirconia reinforcing arm.

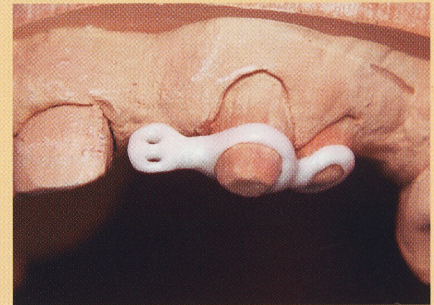


Fig 3. Demonstrates the relatively good fit of the framework to the stone model.

The zirconia frame was constructed by CAD CAM from a wax mock-up (Fig 2). Figure 3 shows the relatively good fit of the zirconia frame to the stone model.

After try in, the abutments were etched for 10 seconds with 37 per cent phosphoric acid gel and after washing and drying with oil free air, the frame was cemented into place using resin based glass ionomer cement (Fig 4).

After application of a dentine bond, the facial aspects of the abutments were sparingly covered with a white tint to mask the zirconia frame (Fig 5).

Application of a white tint below a masking micro hybrid composite resin will maximize the reflection of light back through the micro hybrid and improve the brightness of the resin laminates above.

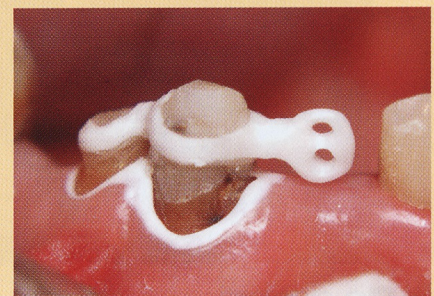


Fig 4. Zirconia framework cemented into place with resin based glass ionomer cement.

Continued from page 33

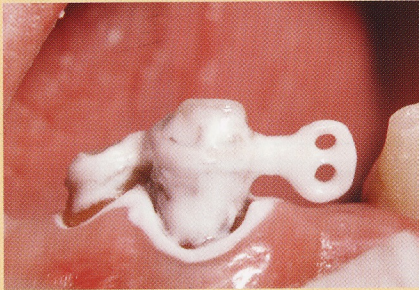


Fig 5. White tint used to mask zirconia bars and enhance reflected light through laminate.

Figure 6 shows the lingual aspect of the completed prosthesis. The gingival floor of the pontic has been constructed using resin modified glass ionomer cement that prevents plaque build up, protects the abutment from caries due to a high fluoride release and of importance clinically, is much easier to finish in this difficult area than composite resin. Clinicians will find it challenging to contour the zirconia frame. Diamond burs produce an impressive display of sparks with little effect on the frame.

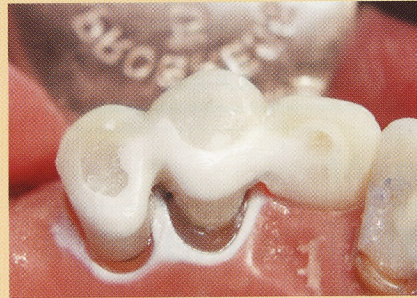

Fig 6. Shows the lingual aspect of completed bridge.

Figure 7 shows the facial aspect of the completed prosthesis. Over the micro hybrid composite base a microfill composite resin was applied to give the restoration a degree of translucency as well as a permanent surface luster. Microfill resins, consist of a high inorganic and low organic components, they use organic instead of metallic dyes and exhibit Rayleigh scattering, creating similar optical properties to tooth enamel. Compromises in aesthetics were made to contain costs in a restoration that was presented to the patient as an experimental intermediate solution.

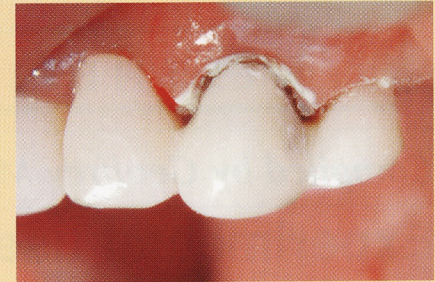

Fig 7. Showing completed intermediate term zirconia reinforced direct resin bridge.

Summary

In summary, it can be said; there are real clinical benefits if these frameworks can be constructed with similar physical dimensions as their metal counterparts. They are certainly easier to mask than metal and if costs remain comparable and the clinical performance is similar they will certainly become the material of choice for this type of clinical situation.

Clinicians should be aware of the experimental nature of this clinical case using zirconia as a restorative material. □