

Compiled by Geoffrey M. Knight

Clinical management of erosion

As people chose to keep their teeth as long as practicable, the management of erosion, attrition and abrasion has become increasingly important in maintaining a functional dentition.

Dental erosion may be defined as the irreversible loss of tooth structure by chemical means that does not involve bacteria and without any associated mechanical factors.

Erosion is caused by either intrinsic gastric acids or extrinsic acid sources.

Intrinsic sources may be due to a gastro oesophageal reflux either spontaneously or self induced due to medical conditions such as anorexia or bulimia nervosa. The development of palatal tooth loss, more severe towards the anterior regions is indicative of intrinsic erosion.

Extrinsic sources can be due to environmental contact with acids at work or during leisure activities from dietary sources associated with the consumption of acidic soft drinks and some dry white wines. It is not just the total consumption of dietary acid substances but the periodicity and the relationship to tooth brushing practices that determines erosion severity. Tooth loss on the anterior facial and palatal aspects is indicative of extrinsic erosion but sites will vary depending how patients hold acidic solutions in their mouths.

Management

Intrinsic acid reflux is best managed by medical referral to a gastroenterologist and possibly psychiatric support. These patients should be encouraged to rinse with water or a solution of sodium bicarbonate after an episode and to avoid immediate tooth cleaning.

Extrinsic erosion can be managed by initiating a thorough dietary analysis that involves keeping an accurate record of food and drink consumption and importantly recording the consumption time. Be aware that some medications such as vitamin C are acidic and prescribed medications can alter salivary flow. Radiation and chemotherapeutics will reduce salivary flow and make patients more susceptible to acidic substances in their mouths.

Lifestyle changes involving increased exercise can predispose patients to dental erosion by a combination of dehydration associated with the consumption of acidic energy fluid replacement supplements. Conversely, drugs such as 'Ecstasy' cause a reduction in saliva flow. When combined with vigorous exercise and acidic drink consumption will predispose to dental erosion.

After dietary analysis, counselling should be tailored to an individual's specific circumstances with a positive bias that will encourage compliance. It is particularly important for patients to reduce the frequency of intake of acidic foods, especially in the evening and to avoid tooth brushing immediately after an acid challenge.

Clinical management

Reduction of further tooth loss after the diagnosis of erosion can be achieved clinically by the application of a high fluoride release glass ionomer cement such as Fuji VII (GC Corp) or Riva Protect. (SDI) These materials are more flowable than conventional auto cure glass ionomer cements enabling them to be painted onto the surface of a tooth in a thin layer over the eroded surface with a micro brush. Upon setting, the GIC will protect the surface of the tooth from external acidic challenges as well as provide an abundance of fluoride ions that may increase tooth resistance to acidic challenge by converting the exposed carbonated apatite crystals on the tooth surface to fluor apatite that has a substantially lower demineralization pH.

Clinical case

The patient is a post graduate student in his mid twenties. He has myasthenia gravis and is taking a medication called 'Mestinon'. Amongst the side effects are increased secretions from endocrine glands, e.g., saliva and sweat. He was taking the final tablet at the evening meal as the excess saliva flow was interfering with his sleep. As a consequence his mouth was drying up and he was sipping from a can of 'Coke' while he studied in the evening.

Figures 1 and 2 show the damage to the lower canines and bicuspids that had occurred since his previous annual examination. The liquid was apparently being held in his cheek pouches.

Preparation of the lower bicuspids and canines consisted of a pumice prophylaxis, etching for five seconds, washing and drying with oil free air prior to isolation with cotton wool rolls. Fuji VII was applied over each eroded surface with a small micro brush and set with the assistance of a photo curing light (Fig 3, 4).

Figures 5 and 6 show the teeth 26 months after initial placement. The glass ionomer cement is still evident on the eroded surfaces protecting them from further acid damage. Where there are ongoing

intrinsic causes of erosion or patients do not comply with suggested dietary changes the covering of glass ionomer cement will require more frequent replacement depending upon the nature of the acidic assault.

Initially, patients should be recalled at three monthly intervals to determine firstly, how the aetiological factors causing the erosion are being managed, and to assess if the protective cover of glass ionomer over the erosion sites requires replacement. If erosion has occurred on the facial aspects of upper anterior teeth a tooth coloured glass ionomer cement will be required. These materials are more challenging to place in thin layers and they don't have the high fluoride release of Fuji VII and Riva Protect.

Disclosure

The author was associated with the development of Fuji VII and has a financial interest in this product.

Figs 1 and 2. Patient presented with significant erosion on the facial surfaces of lower canines and premolars.

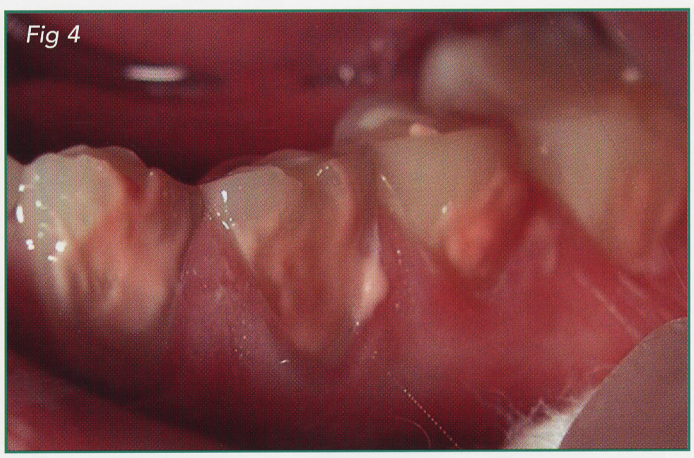

Figs 3 and 4. Following brushing of Fuji VII over eroded tooth surfaces. The glass ionomer cement protects from further erosion and improves acid resistance of the tooth.

Figs 5 and 6. Over two years later, glass ionomer cement layer still protecting underlying tooth surfaces.